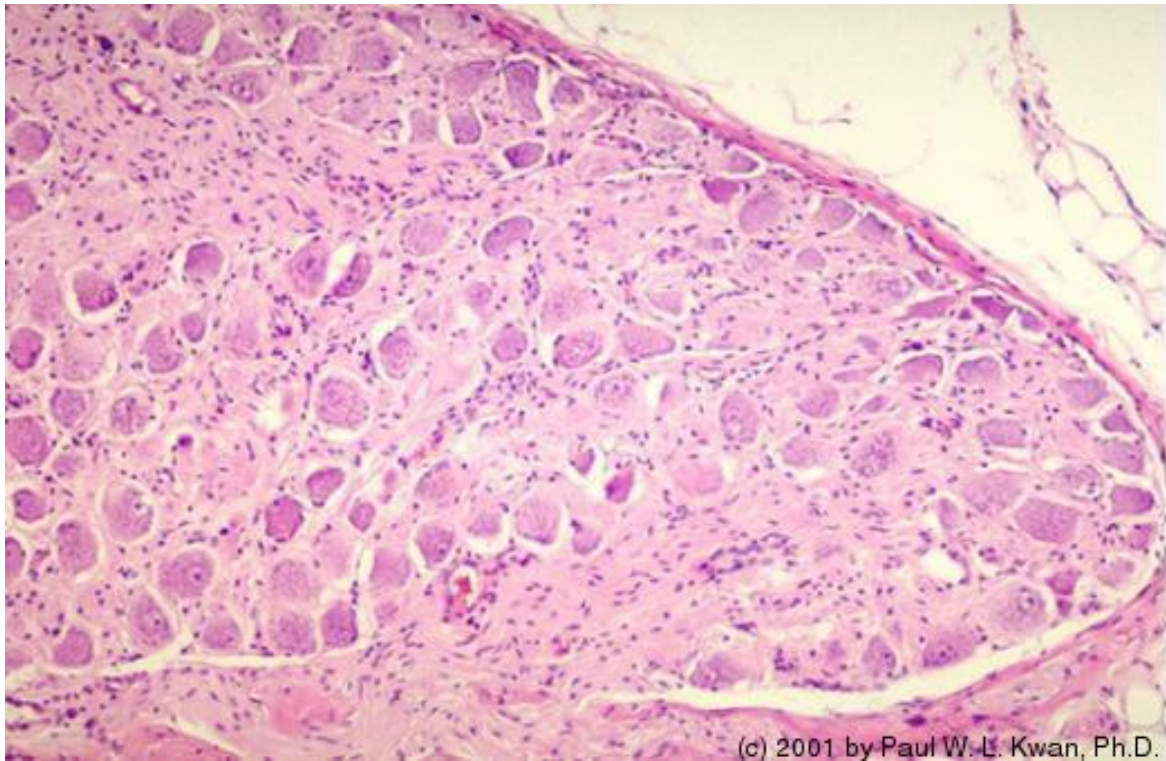
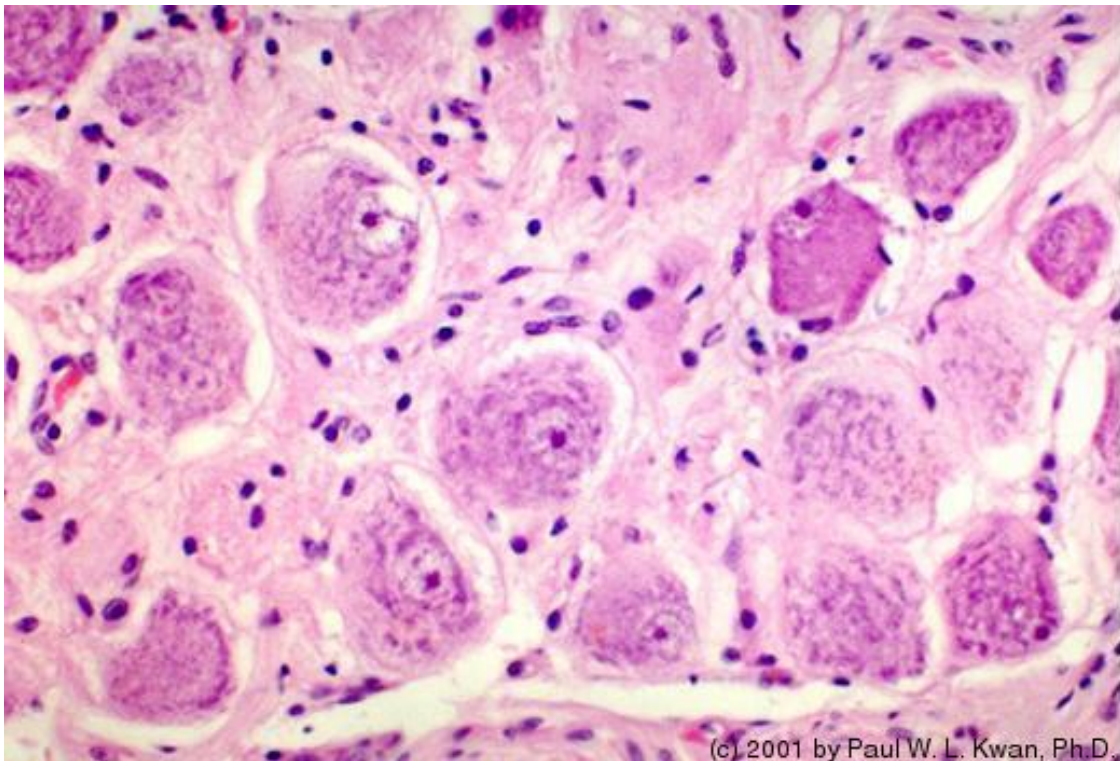


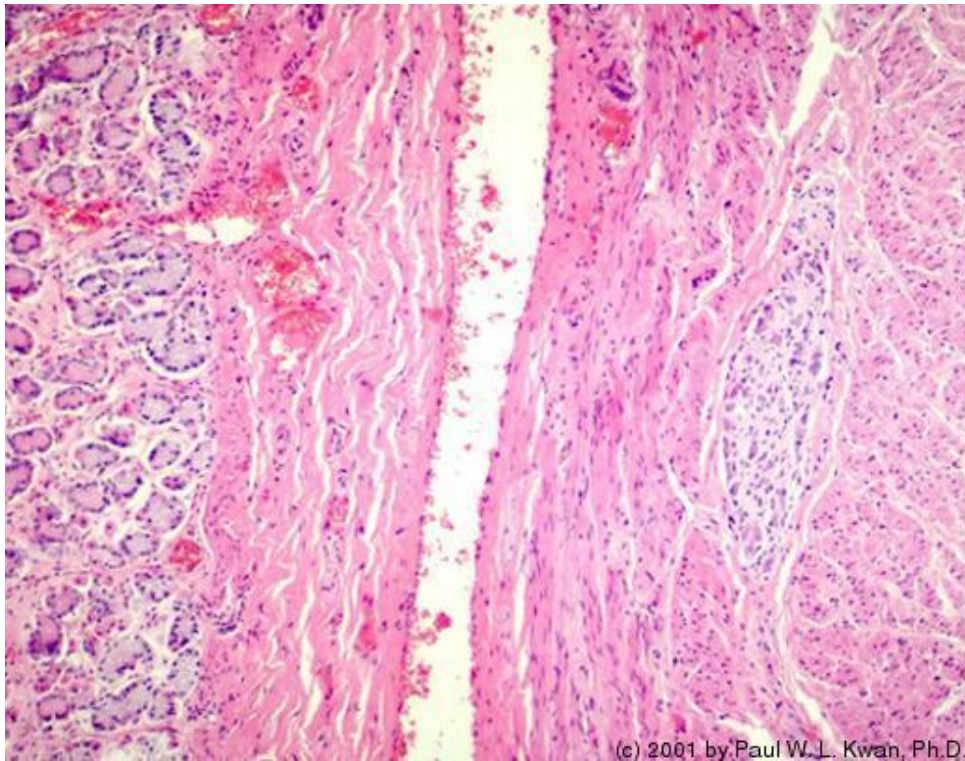
1. Autonomic ganglion in the adrenal gland of the horse



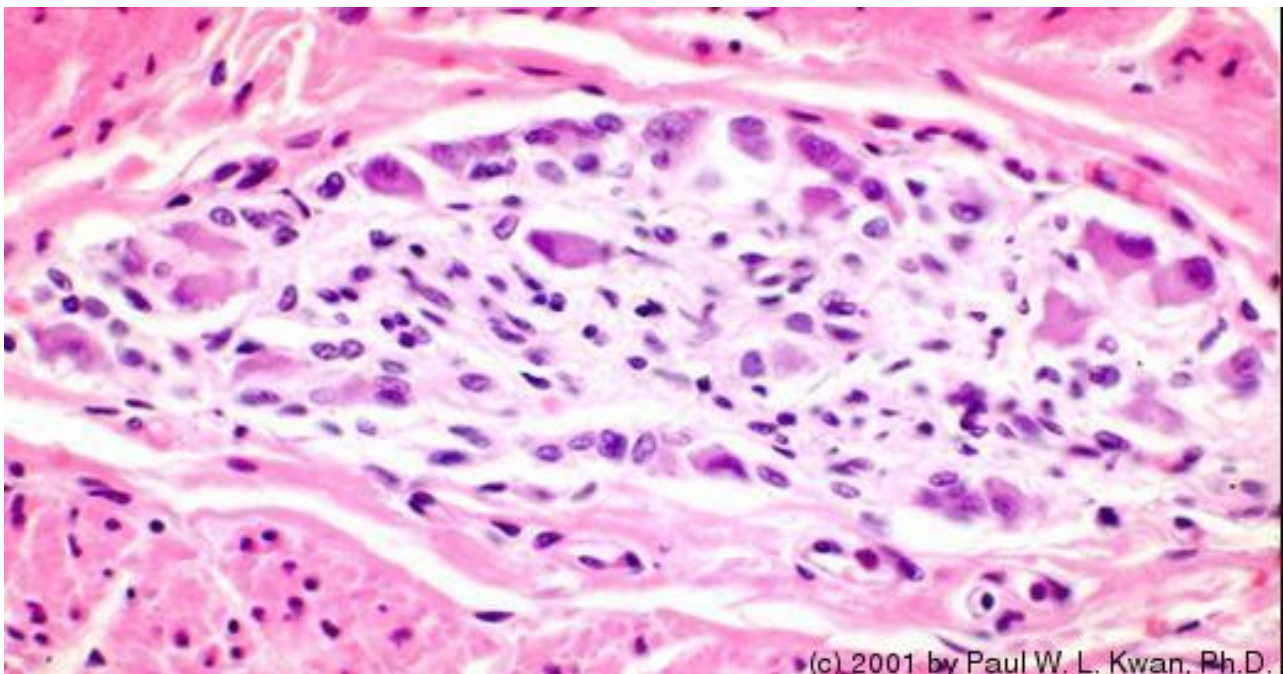
2. Parasympathetic ganglion cells in the adrenal gland of the h...



3. Myenteric plexus of Auerbach in the canine stomach. Low powe...



4. Myenteric plexus of Auerbach in the canine stomach. High powe...



5. Autonomic ganglion in the adrenal gland of the dog

