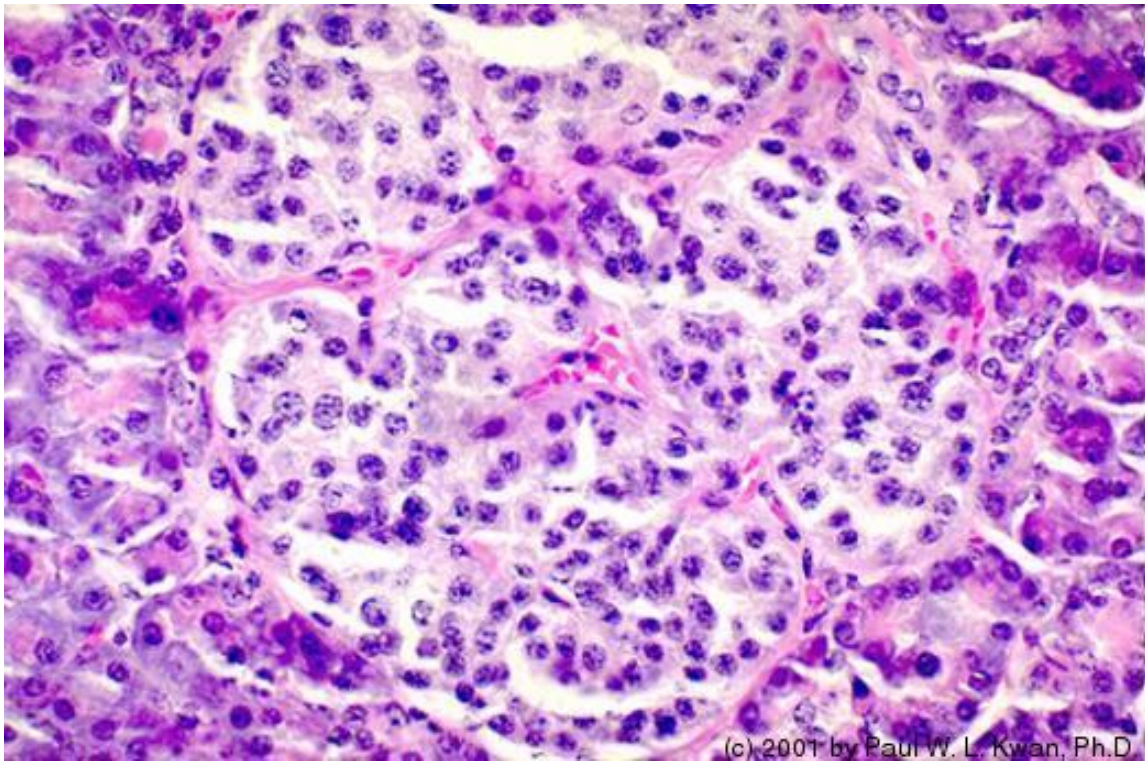
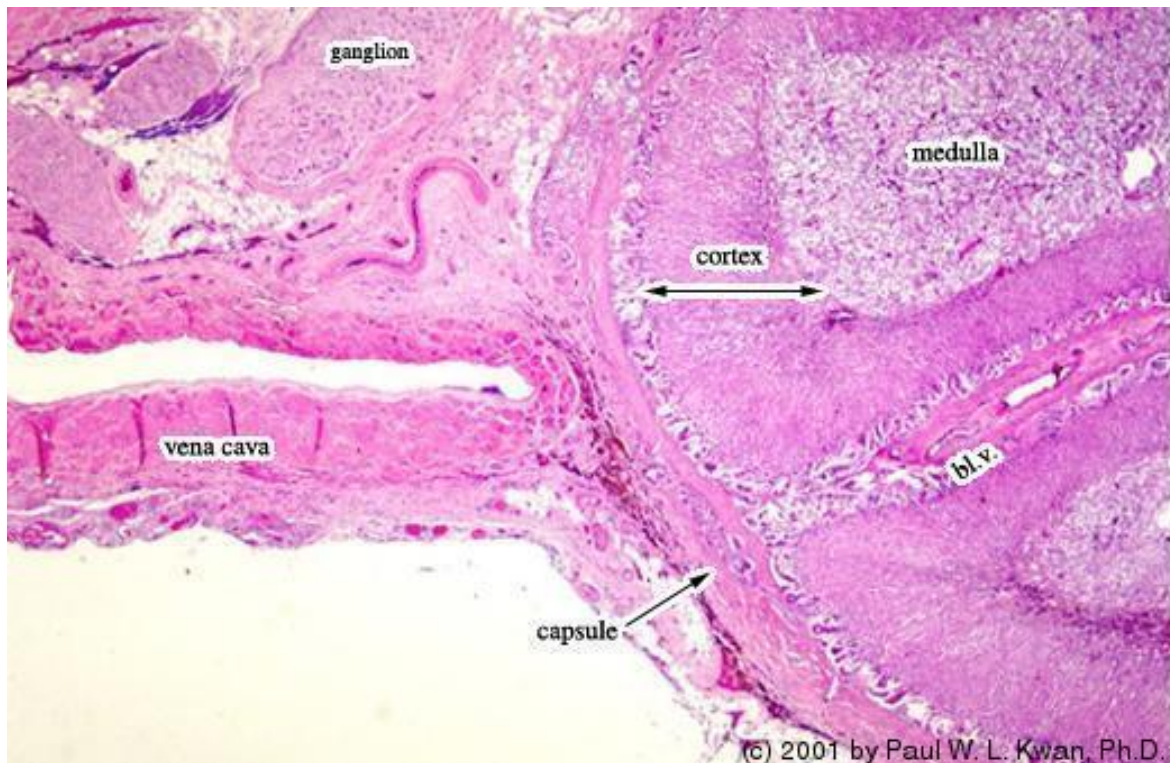

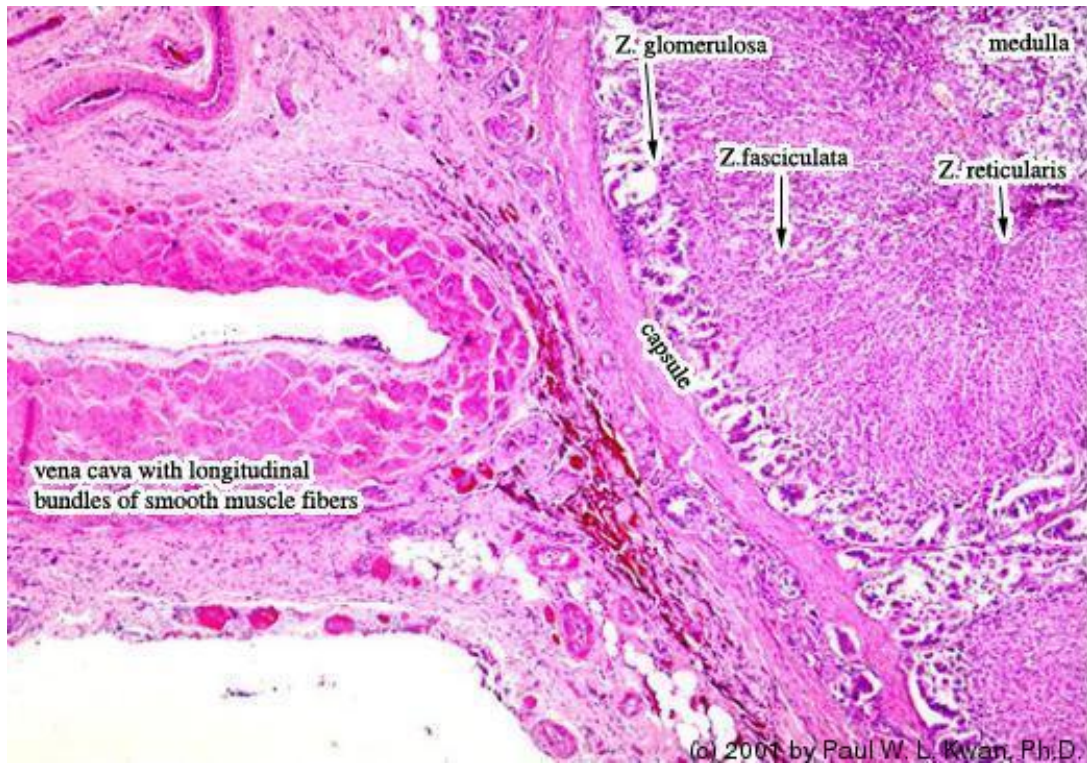
1. Islet of Langerhans in the pancreas of a primate.



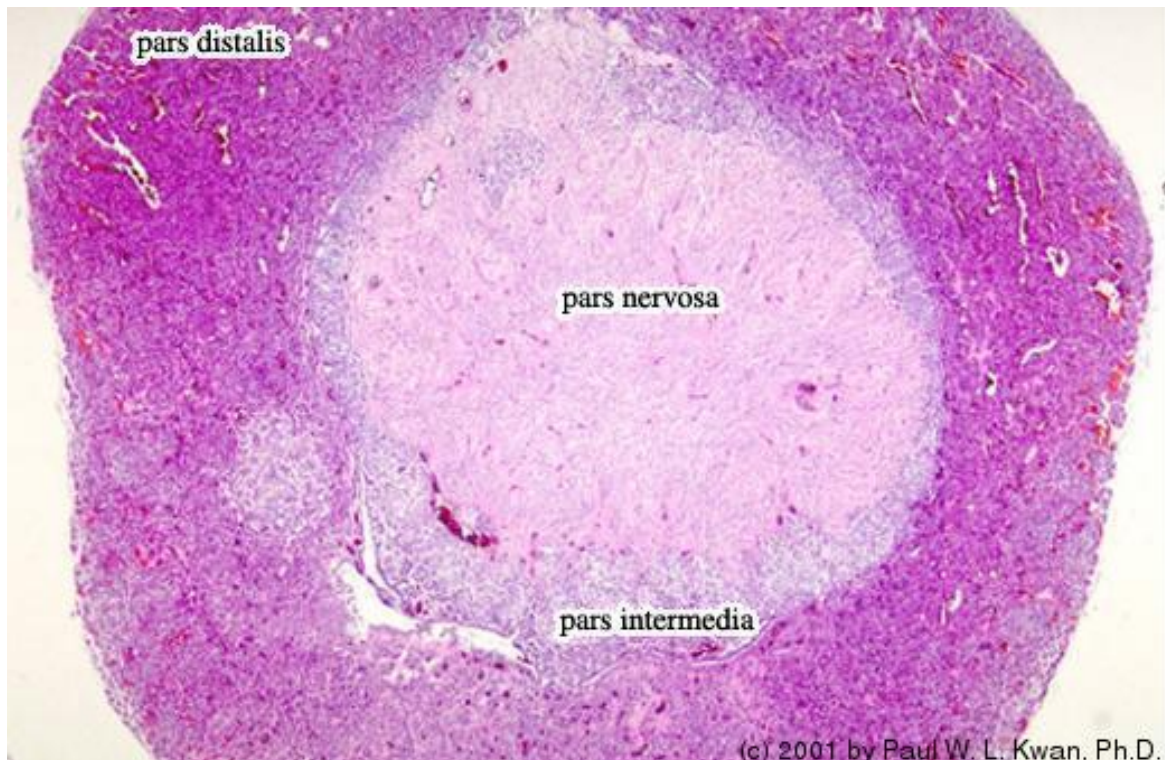
2. Adrenal gland of the horse adjacent to the vena cava



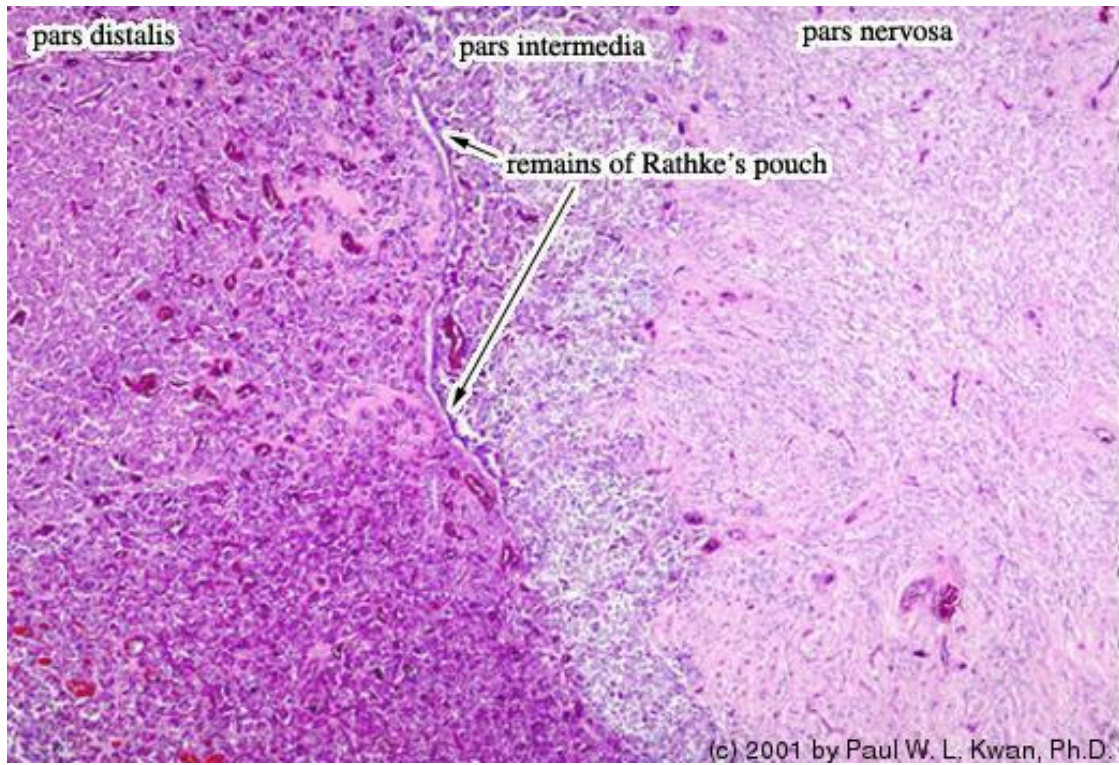
3. Adrenal gland of the horse adjacent to the vena cava



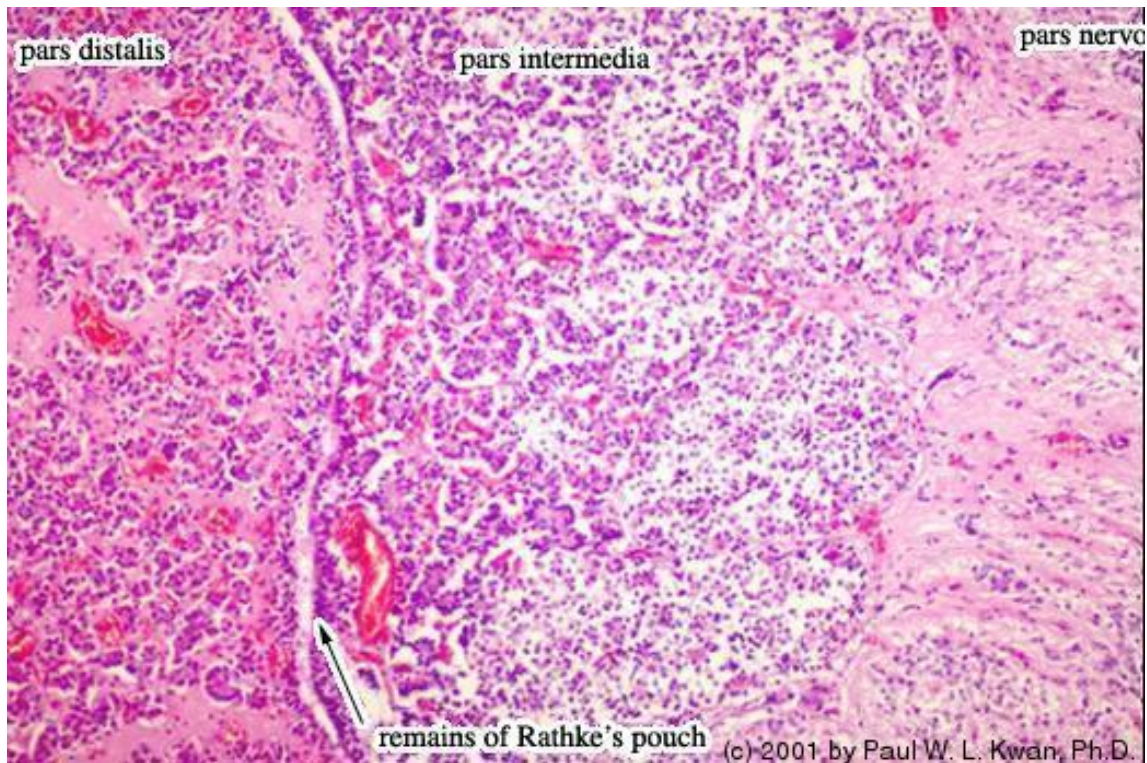
4. Pituitary gland of the horse. Coronal section at low power...



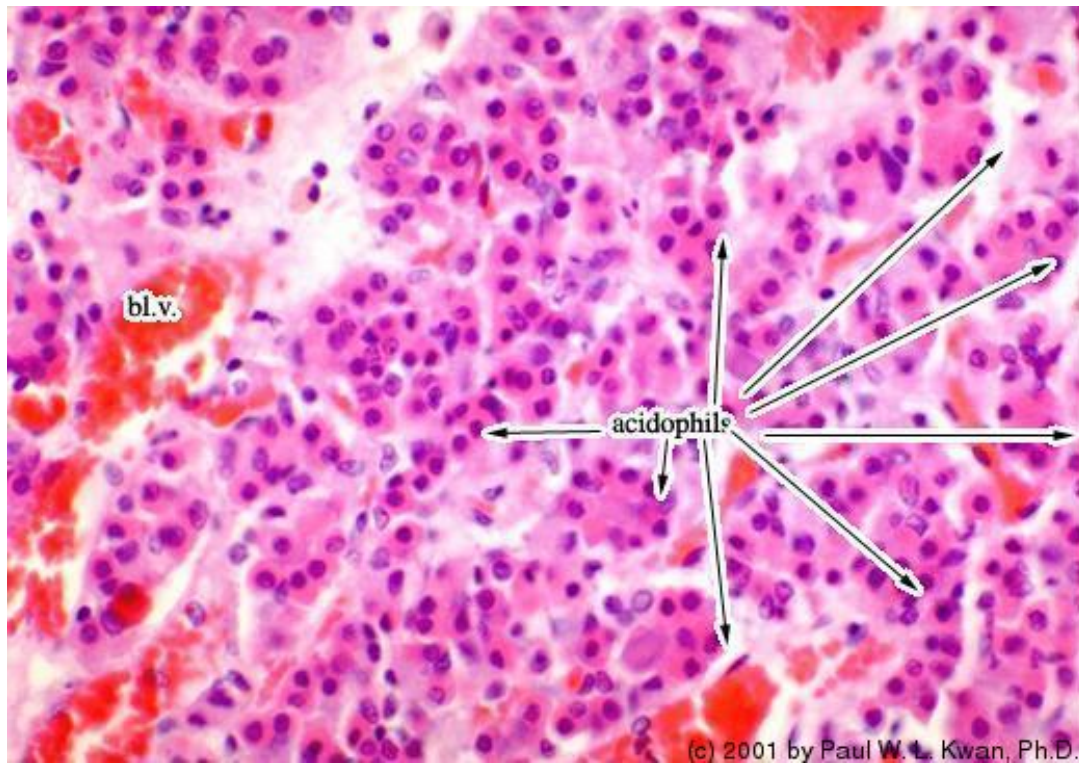
5. Pituitary gland of the horse showing the three main parts



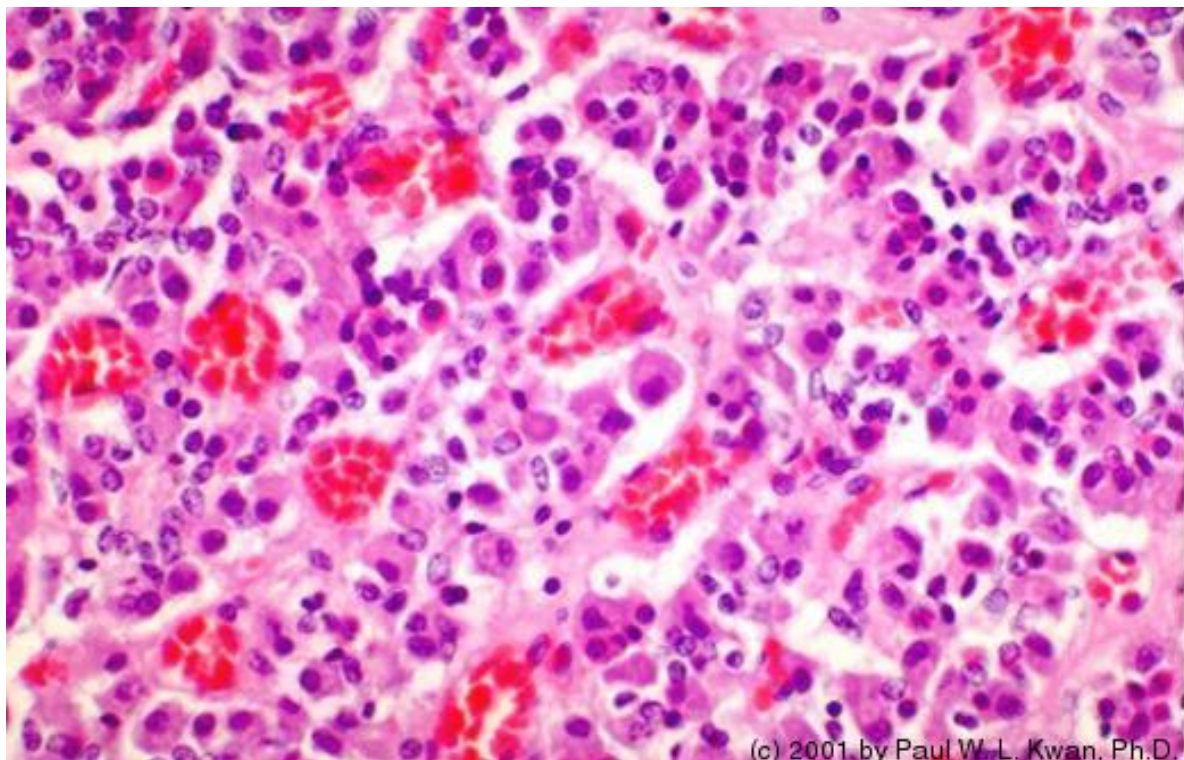
6. Pituitary gland of the horse showing the three main partsat ...



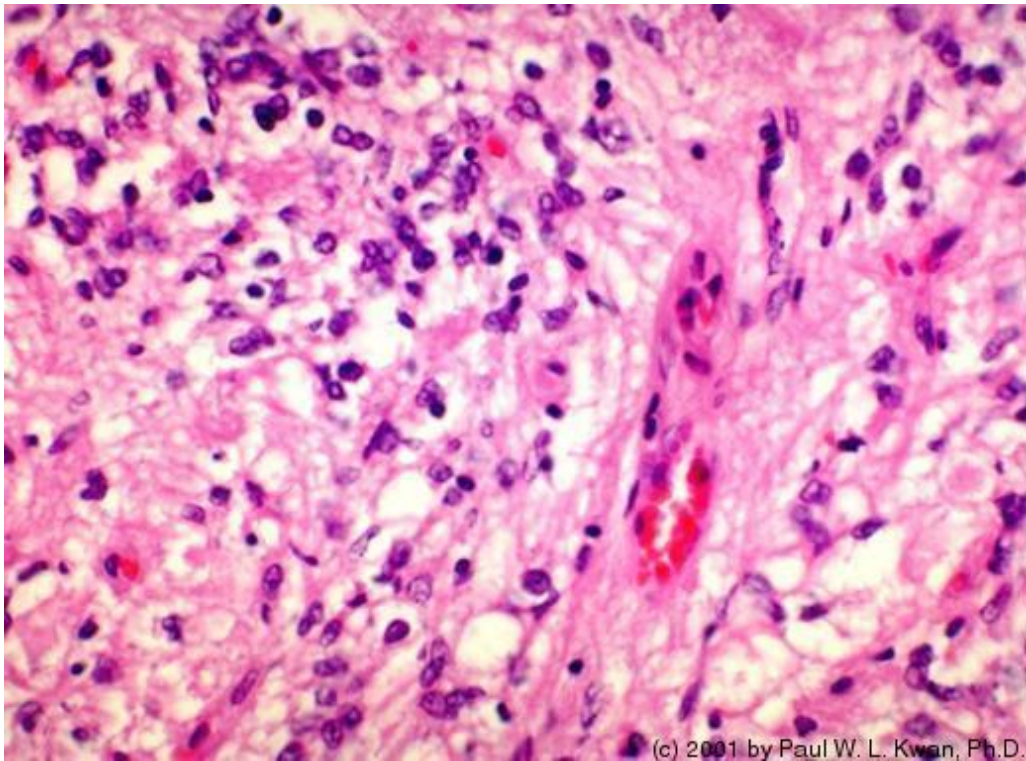
7. Adenohypophysis of the horse with acidophils



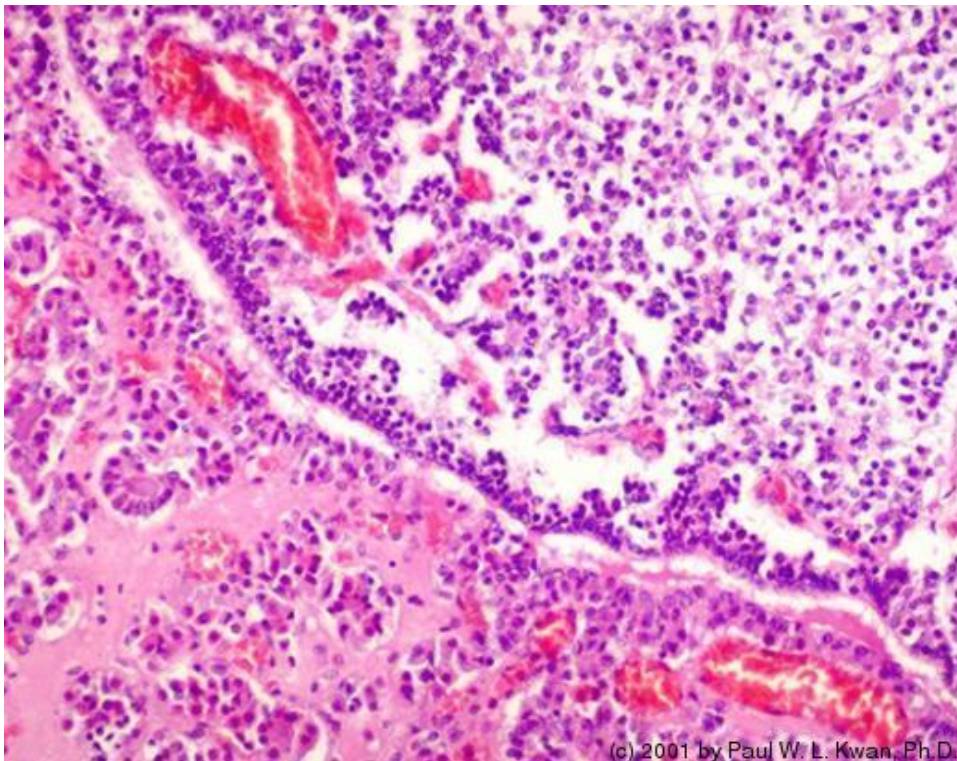
8. Adenohypophysis (pars distalis) of the horse with many acido...



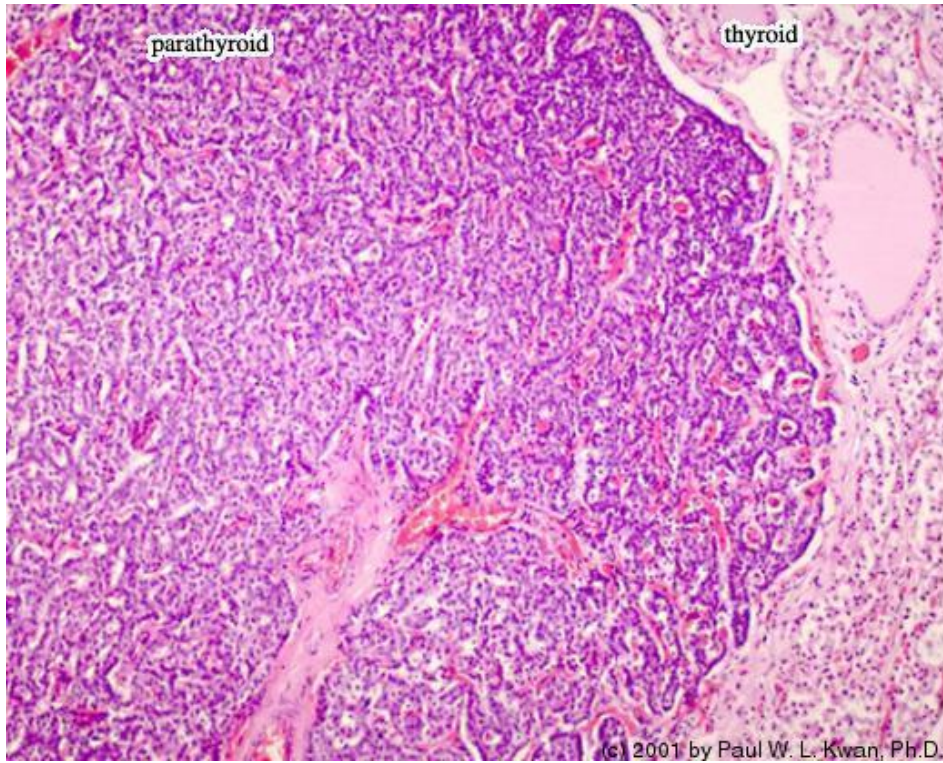
9. Neurohypophysis of the horse with nerve fibers and pituicyte...



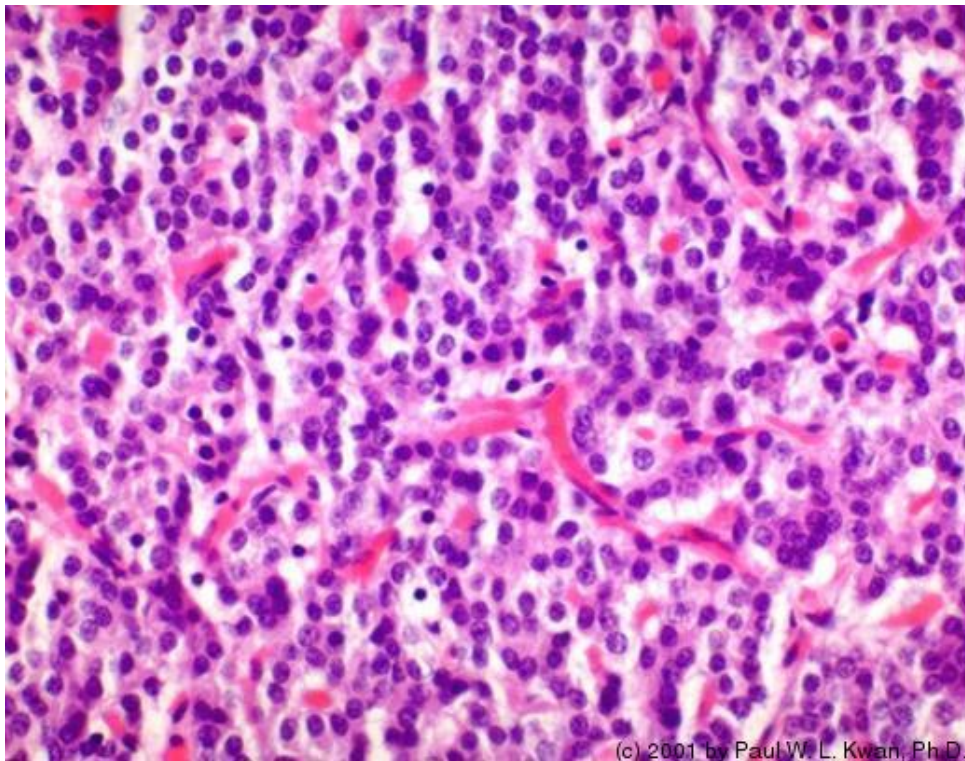
10. Pars intermedia in the pituitary of the horse with remains o...



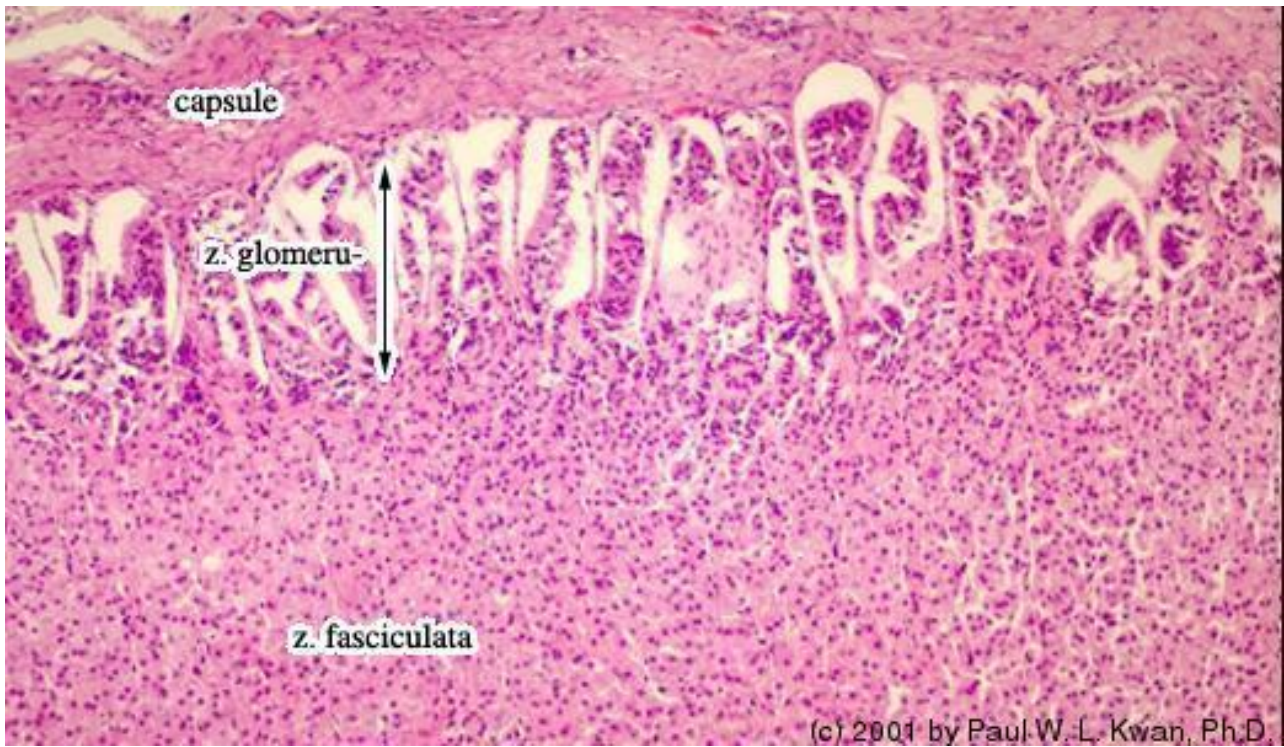11. Parathyroid gland of the horse at low power



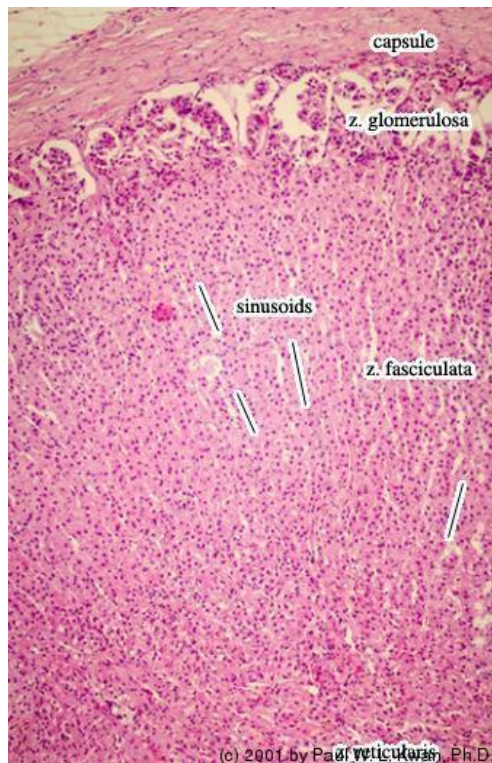
12. Parathyroid gland of the horse



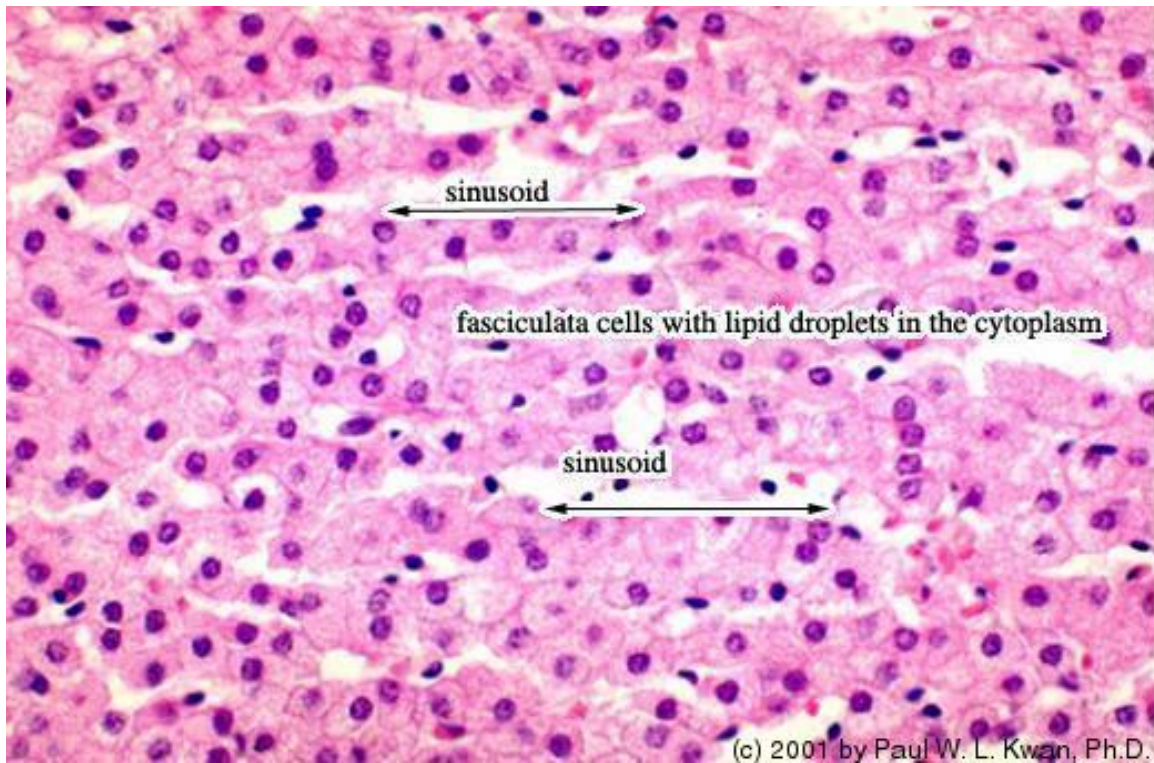
13. Zona glomerulosa in the adrenal cortex of the horse



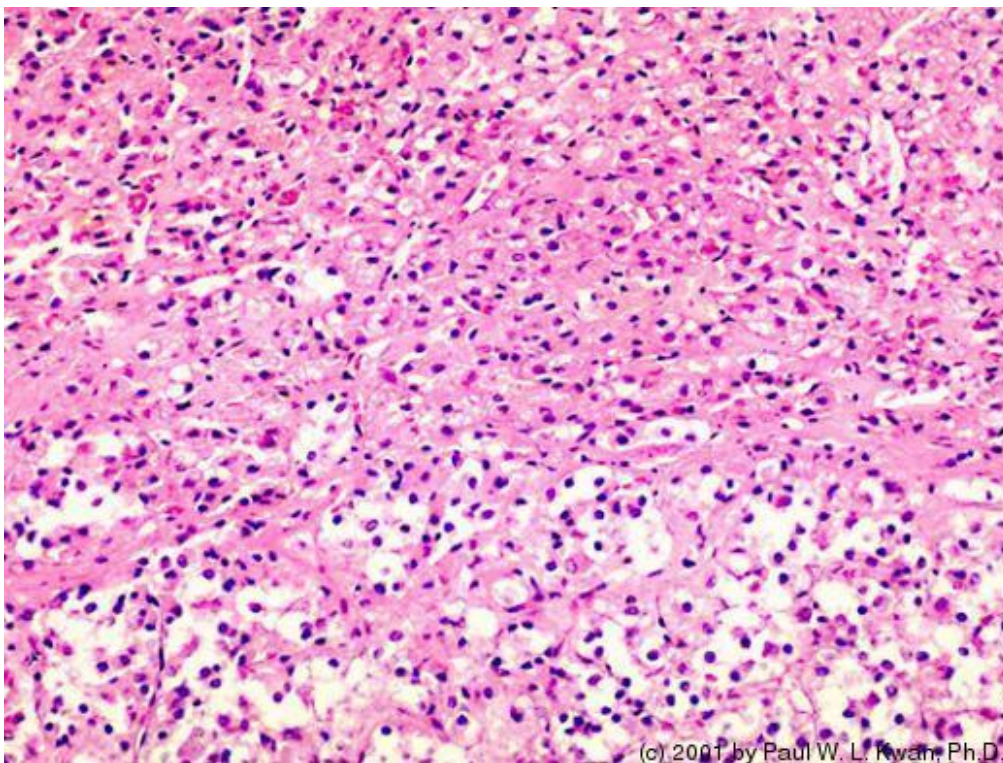
14. Adrenal cortex of the horse showing the three zones



15. Zona fasciculata in the adrenal cortex of the horse

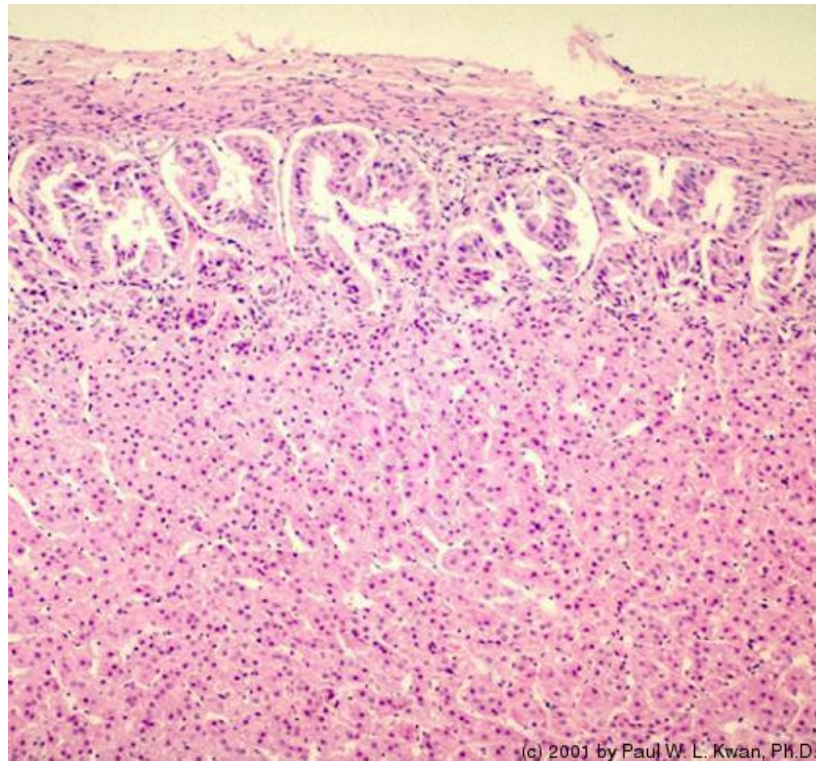


16. Cortex-Medulla junction in the adrenal gland of the horse



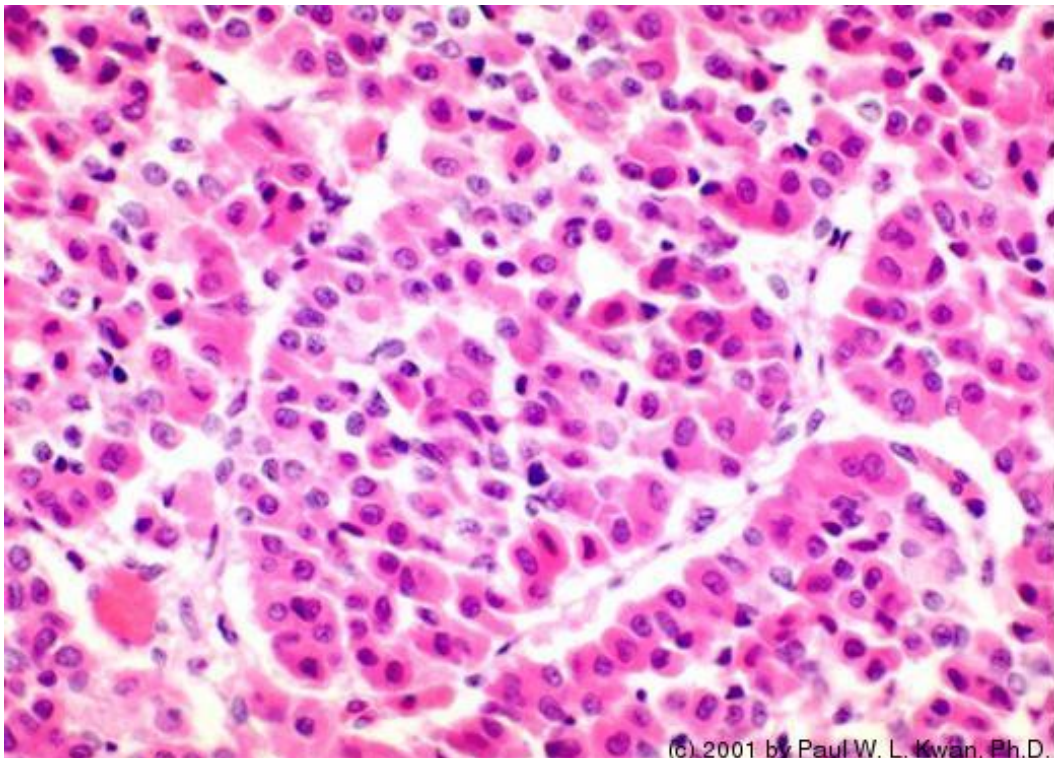
17.

Canine adrenal cortex

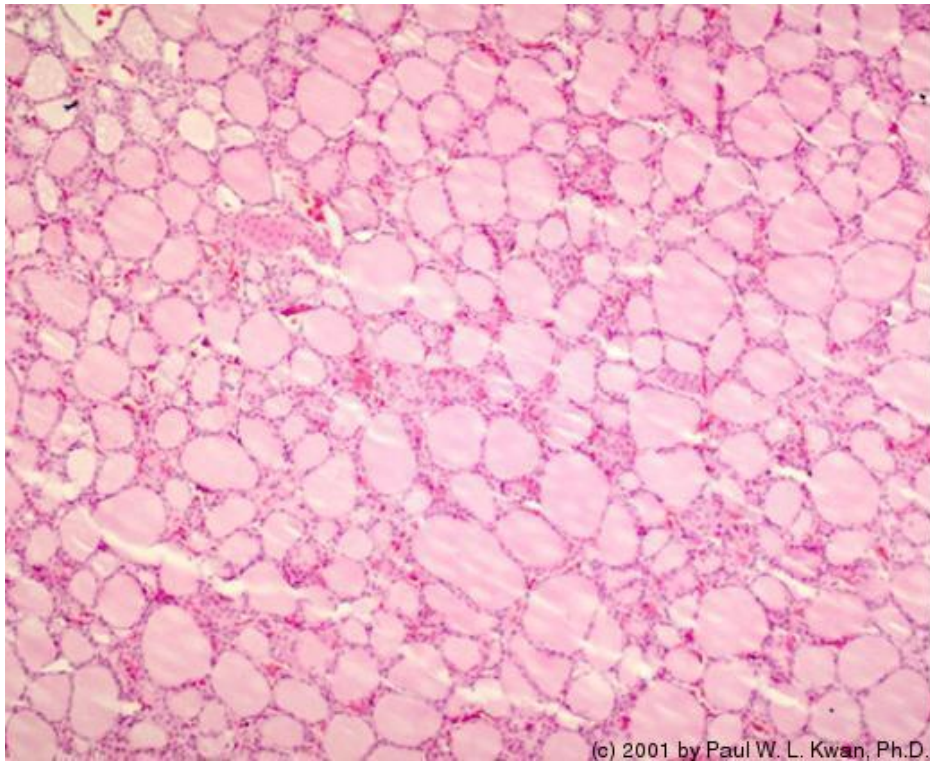


18.

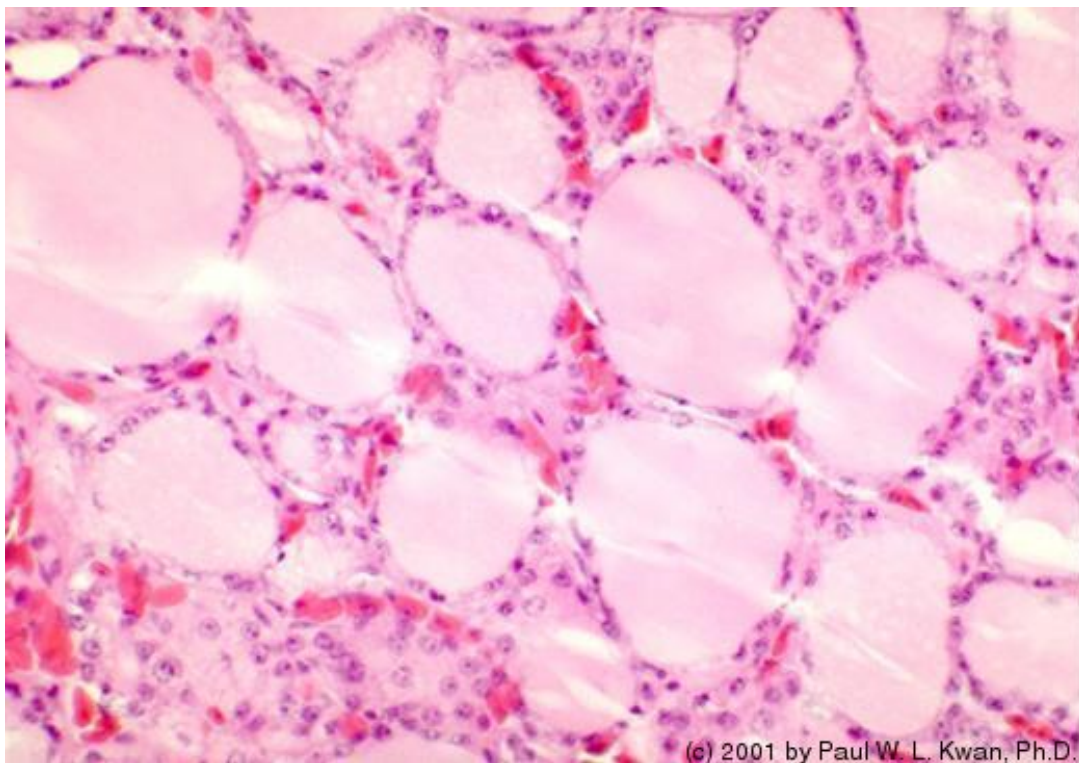
Canine pars distalis with acidophils



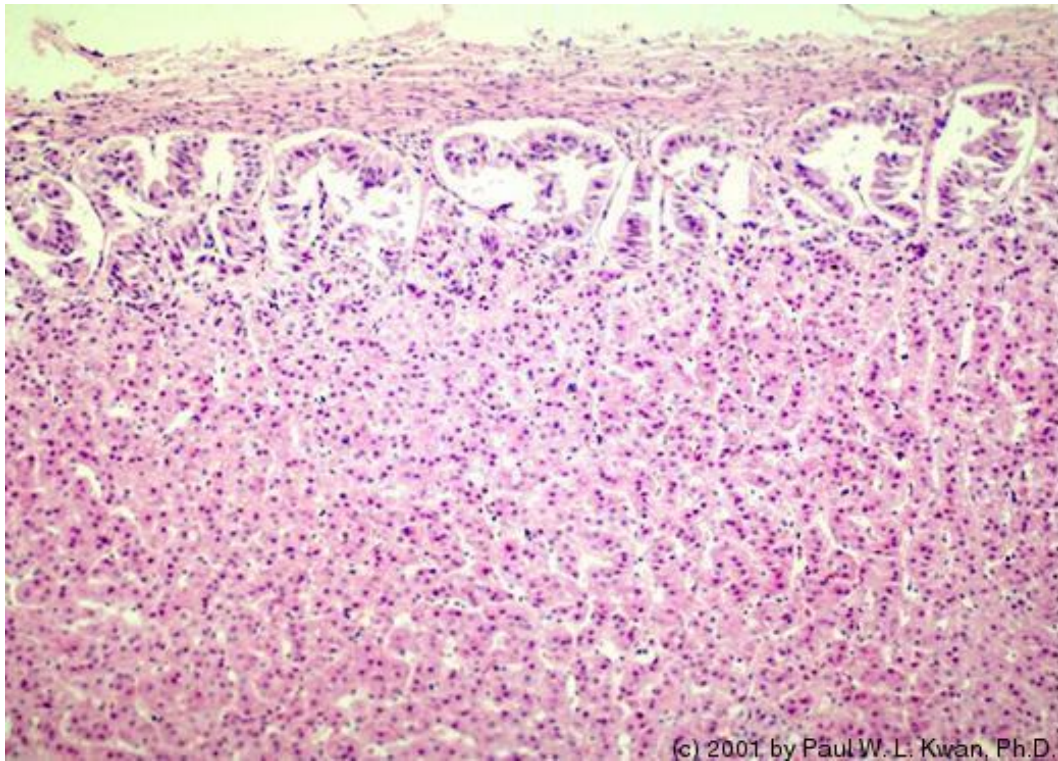
19. Thyroid gland of Canadian goose



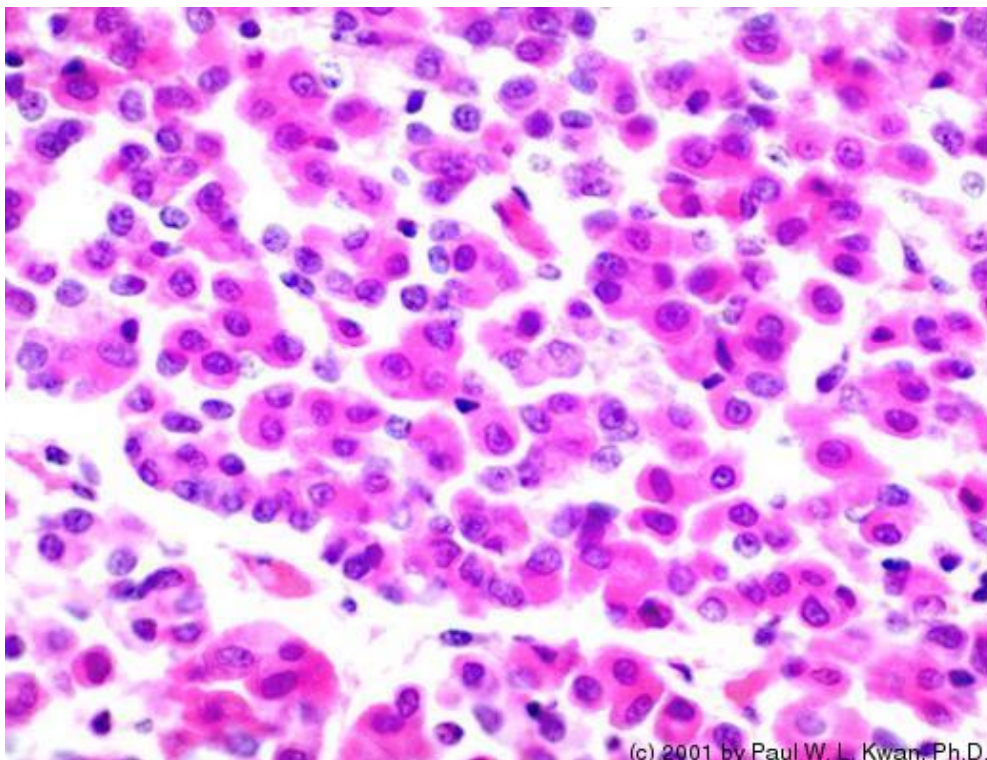
20. Thyroid follicles from a Canadian goose



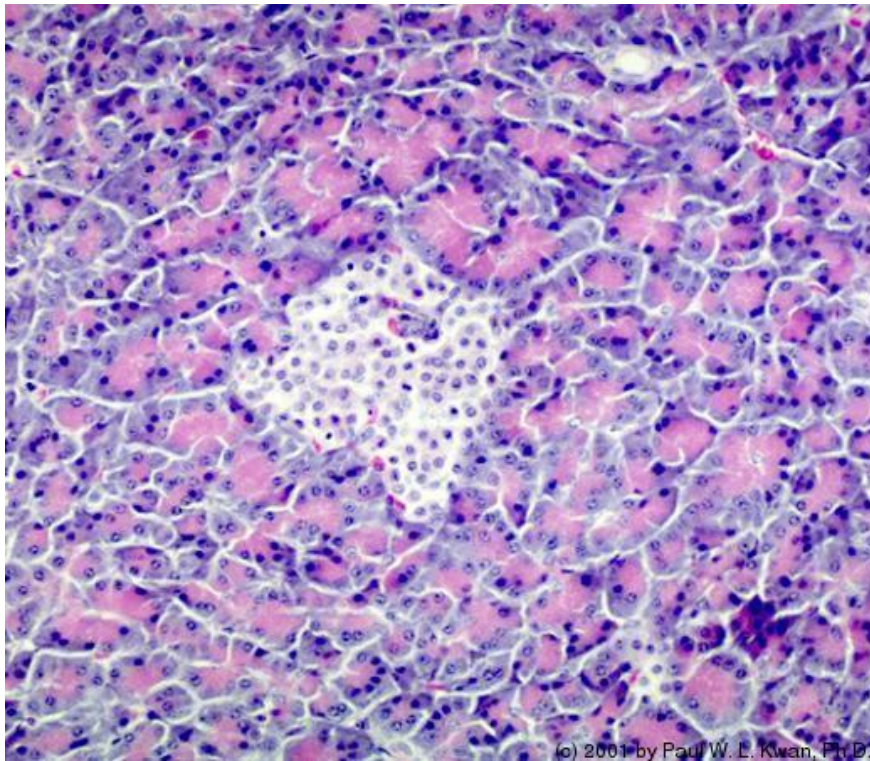
21. Canine adrenal cortex with zona glomerulosa and zona fascicu...



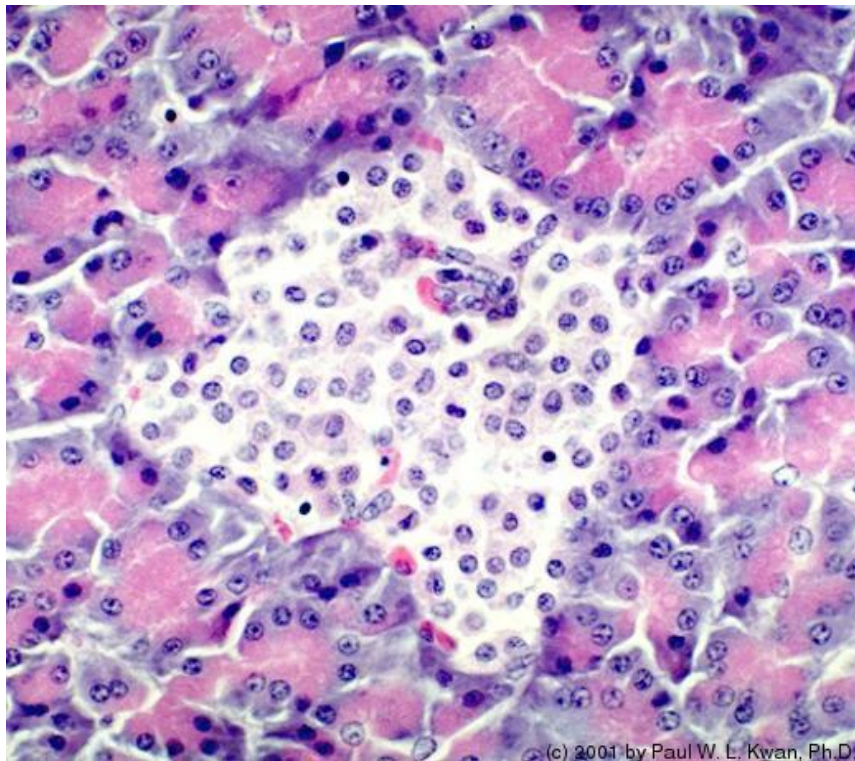
22. Acidophils in the pars distalis of the canine pituitary



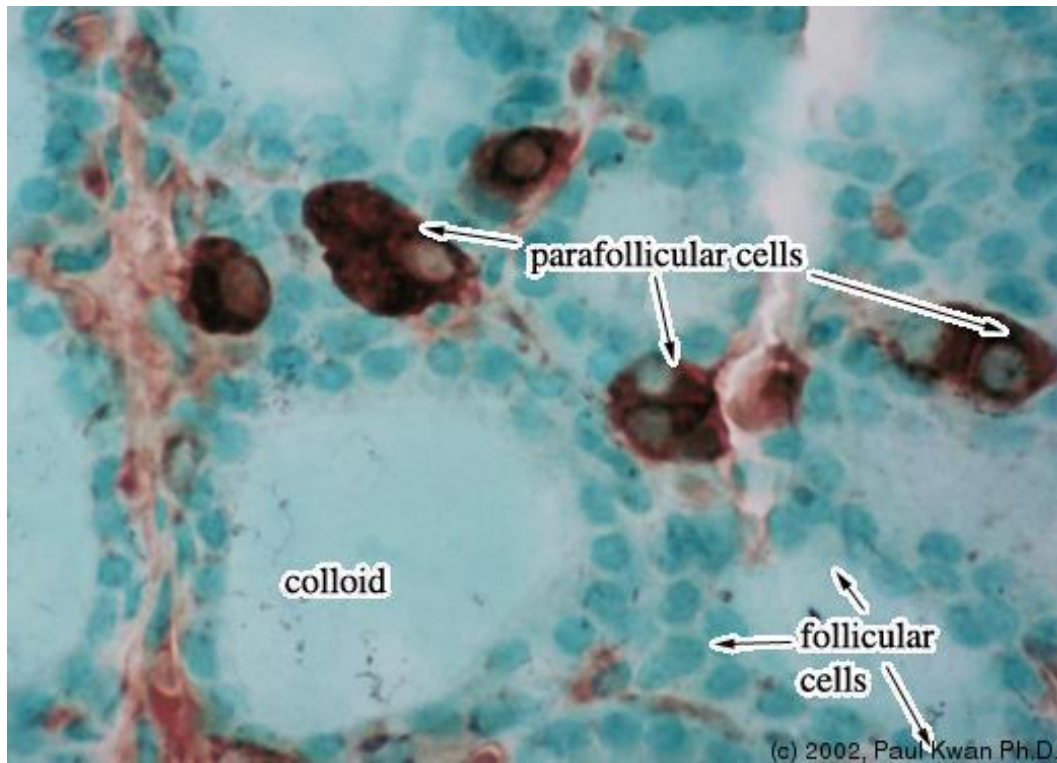
23. Islet of Langerhans in canine pancreas



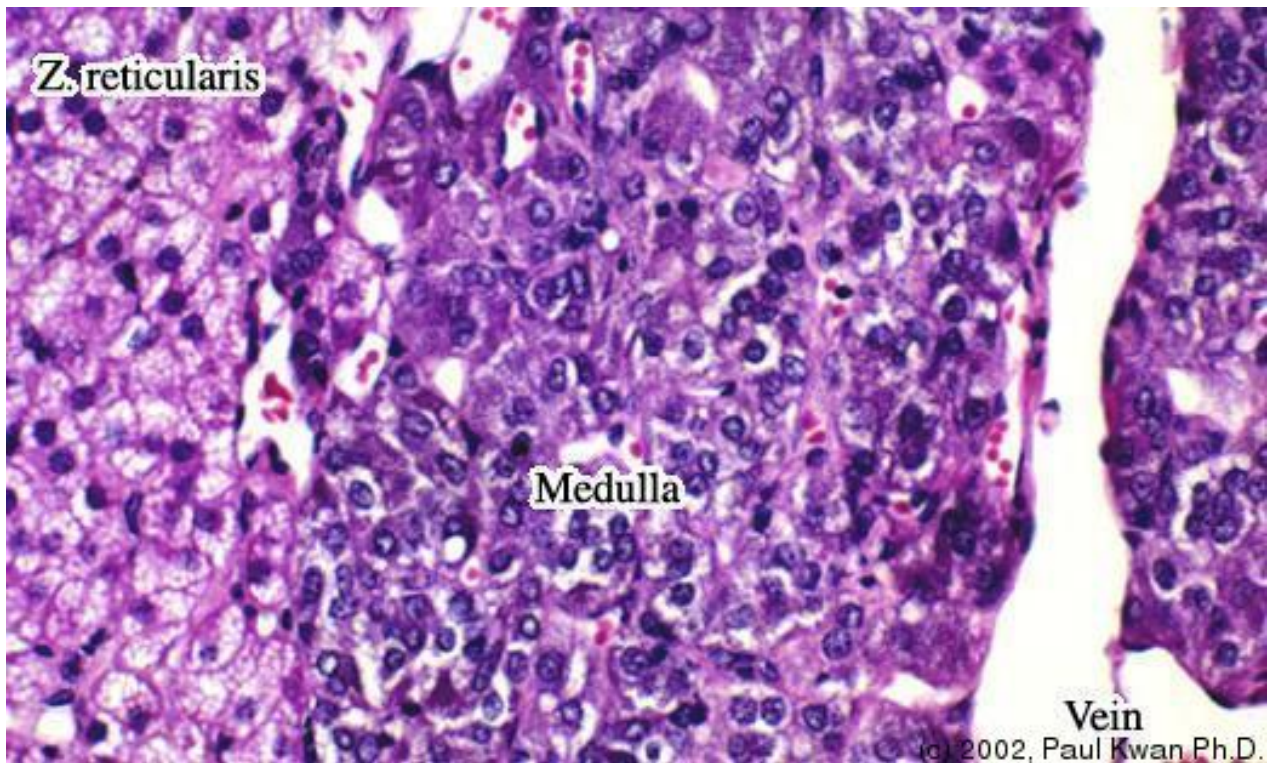
24. Islet of Langerhans in canine pancreas at higher magnificati...



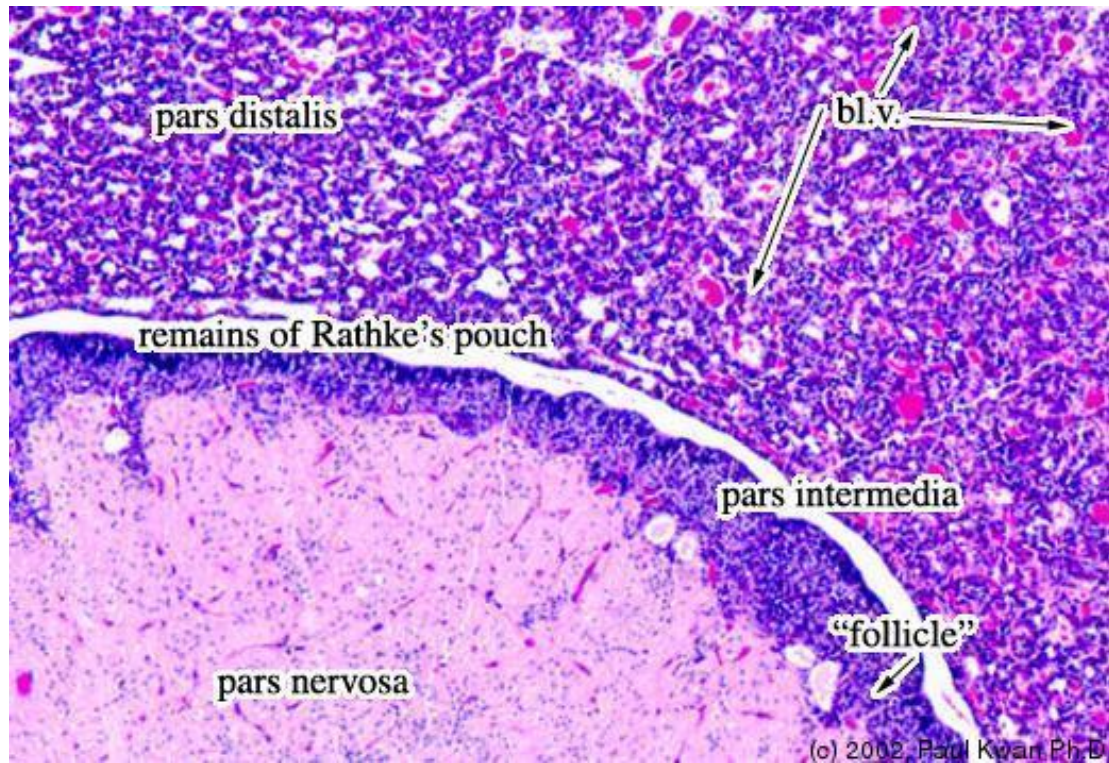
25. Immunohistochemical Staining of Parafollicular Cells.



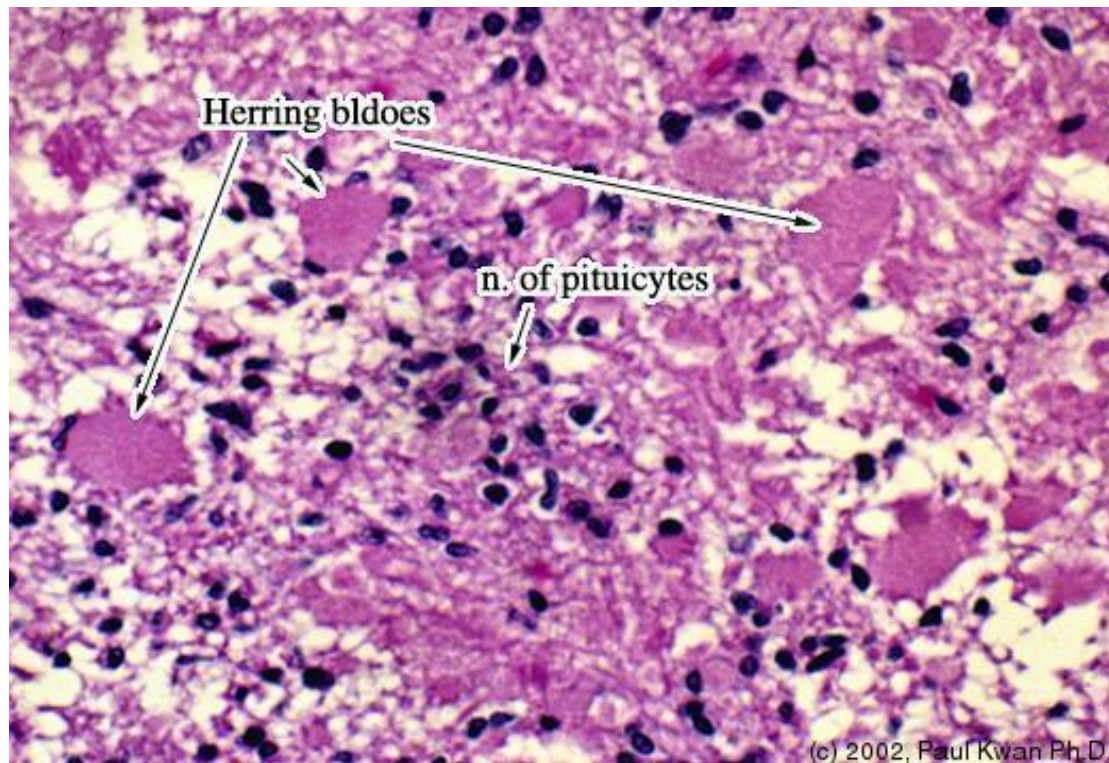
26. Junction Between Z. Reticularis and the Medulla



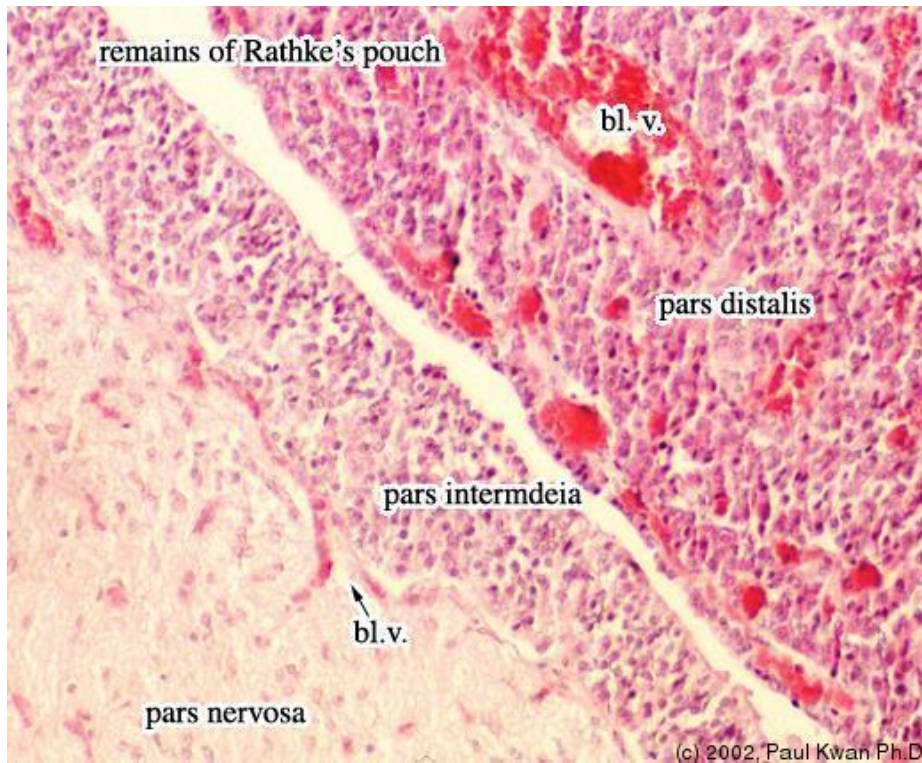
27. Low Power Micrograph of Canine Pituitary.



28. Herring bodies in the neurohypophysis of a dog.



29. Canine pituitary gland containing adeno- and neuro-hypophys...



30. Parafollicular cells among thyroid follicles.

