


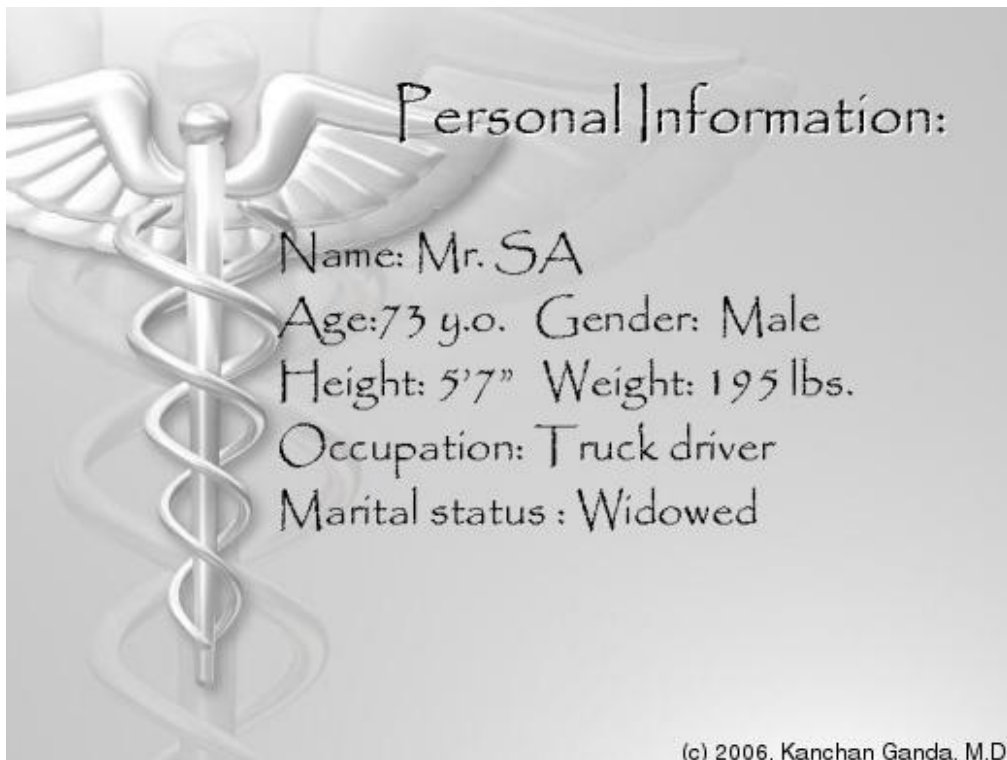
1.

Dental Record Review -1



2.

Personal Information:



3.

Chief Concern:



Chief Concern:

“I want to fix my back teeth.”

(c) 2006, Kanchan Ganda. M.D.

4.

Medical History



Medical History

- ◆ 1° Stage II Hypertension
- ◆ Type II Diabetes
- ◆ Functional Heart Murmur
- ◆ Hypercholesteremia
- ◆ Gout
- ◆ Tremors
- ◆ Rheumatic fever as a child w/o RHD
- ◆ Stroke - 6 years ago

(c) 2006, Kanchan Ganda. M.D.

5.

Dental History



Dental History

- ◆ Extensive Restorations
- ◆ Last dental visit: July 2006
- ◆ Date of last cleaning Nov 2005

(c) 2006, Kanchan Ganda. M.D.

The slide features a background with a caduceus symbol on the left and a faint image of a dental chair on the right. The text is presented in a serif font.

6.

Social History



Social History

- ◆ Smokes a pipe during all waking hours for the past 20 years.

(c) 2006, Kanchan Ganda. M.D.

The slide features a background with a caduceus symbol on the left and a faint image of a dental chair on the right. The text is presented in a serif font.

7.

Medications



Medications

- Warfarin sodium 5mg qd
- Allopurinol 300mg qd
- Lisinopril 20mg qd
- Simvastatin 20mg qd
- Glipizide 5mg qd
- Duloxetine hydrochloride 30mg bid

(c) 2006, Kanchan Ganda. M.D.

8.

Physical Examination



Physical Examination

- ◆ Pulse: 81 beats/min
- ◆ BP: 163/84
- ◆ Respiration: 15 breaths/min
- ◆ ASA II status
- ◆ Wears glasses

(c) 2006, Kanchan Ganda. M.D.

9.

Lab Values



Lab Values

- ◆ HbA1C: 7.3%
- ◆ PT/INR: 3.1

(c) 2006, Kanchan Ganda. M.D.

10.

Planned Dental Tx



Planned Dental Tx

- ◆ Scaling and Root Planing
- ◆ Amalgam Restorations
- ◆ Caries Control
- ◆ Removable Partial Denture

(c) 2006, Kanchan Ganda. M.D.

11.

Red Flags




Red Flags

- ◆ Hypertension
- ◆ Moderately Uncontrolled Type II Diabetes
- ◆ Smoker of 20 years

(c) 2006, Kanchan Ganda. M.D.

12.

AAA's



AAA's

I. Warfarin sodium

- ◆ Anesthetics: No significant CI
- ◆ Analgesics: No aspirin or NSAIDs. No long term use of acetaminophen.
- ◆ Antibiotics: No Macrolides, quinolones, tetracyclines
- ◆ Avoid antifungals

(c) 2006, Kanchan Ganda. M.D.

13.

AAA's

AAA's

II. Allopurinol

- ◆ Anesthetics: No significant CI
- ◆ Analgesics: No significant CI
- ◆ Antibiotics: No significant CI

(c) 2006, Kanchan Ganda. M.D.

14.

AAA's

AAA's

III. Lisinopril

- ◆ Anesthetics: No significant CI
- ◆ Analgesics: No Aspirin or NSAIDs. Use acetaminophen
- ◆ Antibiotics: No tetracyclines or quinolones

(c) 2006, Kanchan Ganda. M.D.

15.

AAA's

AAA's

IV. Simvastatin

- ◆ Anesthetics: No significant CIs
- ◆ Analgesics: No significant CIs
- ◆ Antibiotics: No Macrolides, metronidazole
- ◆ Avoid Antifungals

(c) 2006, Kanchan Ganda. M.D.

16.

AAA's

AAA's

V. Glipizide (Moderately Uncontrolled Diabetic)

- ◆ Anesthetics: Avoid Xylocaine, Prilocaine HCL or Bupivacaine HCl ONLY. Max 2 carpules
- ◆ Analgesics: No NSAIDs, aspirin
- ◆ Antibiotics: No significant CI
- ◆ Avoid antifungals

(c) 2006, Kanchan Ganda. M.D.

17.

AAA's



AAA's

VI. Duloxetine hydrochloride

- ◆ Anesthetics: No Lidocaine, Bupivacaine HCl, Articaine (avoid epi)
- ◆ Analgesics: No significant CI
- ◆ Antibiotics: No significant CI

(c) 2006, Kanchan Ganda. M.D.

18.

Drug-Drug Interactions



Drug-Drug Interactions

- Warfarin sodium is potentiated by allopurinol and simvastatin
- Warfarin sodium decreases the metabolism of glipizide
- Lisinopril may potentiate hypersensitivity to allopurinol

(c) 2006, Kanchan Ganda. M.D.

19.

Final AAA's



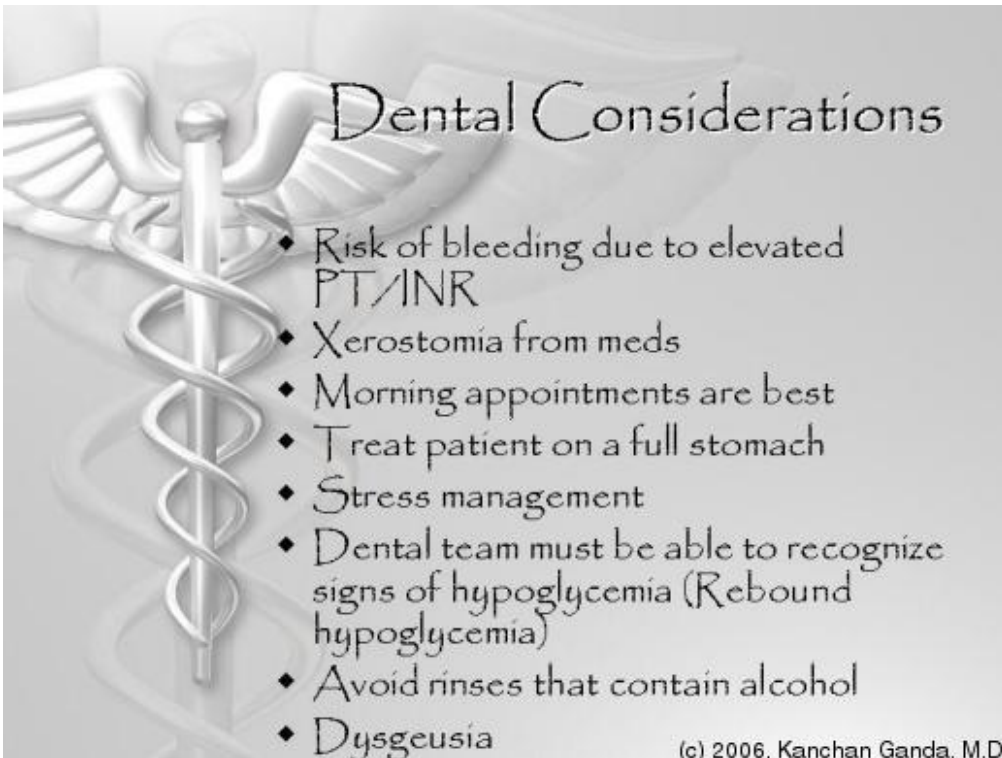
Final AAA's

- ◆ Anesthetic: Mepivacaine HCL
- ◆ Analgesic: Regular acetaminophen
- ◆ Antibiotic: Amoxicillin, Clindamycin
- ◆ Avoid Antifungals

(c) 2006, Kanchan Ganda. M.D.

20.

Dental Considerations



Dental Considerations

- ◆ Risk of bleeding due to elevated PT/INR
- ◆ Xerostomia from meds
- ◆ Morning appointments are best
- ◆ Treat patient on a full stomach
- ◆ Stress management
- ◆ Dental team must be able to recognize signs of hypoglycemia (Rebound hypoglycemia)
- ◆ Avoid rinses that contain alcohol
- ◆ Dysgeusia

(c) 2006, Kanchan Ganda. M.D.